

# Sporadic and Infectious Human Prion Diseases

**Robert G. Will and James W. Ironside**

National Creutzfeldt–Jakob Disease Research and Surveillance Unit, Centre for Clinical Brain Sciences, University of Edinburgh, Western General Hospital, Edinburgh EH4 2XU, United Kingdom

*Correspondence:* r.g.will@ed.ac.uk; james.ironside@ed.ac.uk

Human prion diseases are rare neurodegenerative diseases that have become the subject of public and scientific interest because of concerns about interspecies transmission and the unusual biological properties of the causal agents: prions. These diseases are unique in that they occur in sporadic, hereditary, and infectious forms that are characterized by an extended incubation period between exposure to infection and the development of clinical illness. Silent infection can be present in peripheral tissues during the incubation period, which poses a challenge to public health, especially because prions are relatively resistant to standard decontamination procedures. Despite intense research efforts, no effective treatment has been developed for human prion diseases, which remain uniformly fatal.

**H**uman prion diseases are clinically and epidemiologically diverse, but are linked by shared neuropathological features, including spongiform degeneration, astrocytic gliosis, and neuronal loss, sometimes associated with amyloid plaques. These histological changes are caused by the deposition of a posttranslationally modified form of a normal host protein, prion protein (PrP<sup>C</sup>). This modified protein, PrP<sup>Sc</sup>, is disease-specific and is the major (if not the sole) component of the transmissible agent in human and animal prion diseases. The identification of PrP<sup>Sc</sup> by immunohistochemical and biochemical techniques is a key component of the tissue-based diagnosis of prion diseases.

The archetypal human prion disease is sporadic Creutzfeldt–Jakob disease (sCJD), which was first identified in 1920 (Creutzfeldt 1920; Jakob 1921), and was regarded as a rare, atypical form of dementia until it was shown in

1968 (Gibbs et al. 1968) to be experimentally transmissible to primates by intracerebral inoculation. This finding followed the earlier transmission of kuru to primates in 1966 (Gajdusek et al. 1966), which was the first demonstration that degenerative disorders might be caused by infectious agents. This seminal discovery prompted a search for the source of infection in sCJD through epidemiological studies, but these analyses have not identified any consistent risk factor for the development of this disease (de Pedro Cuesta et al. 2012).

The occurrence of acquired cases of CJD caused by previous medical or surgical treatments, such as with human pituitary hormones (Brown et al. 2000), led to awareness of the potential public health implications of diseases with extended incubation periods and a fatal outcome. Public and regulatory concern about these disorders has increased with the identification of variant CJD (vCJD) as a zoonosis

causally linked to bovine spongiform encephalopathy (Will et al. 1996), although the decline in the annual numbers of these cases (Will 2010) has been paralleled by a waning of general interest; however, there are many residual uncertainties, and it may be premature to dismiss all concerns for public health.

## SPORADIC HUMAN PRION DISEASES

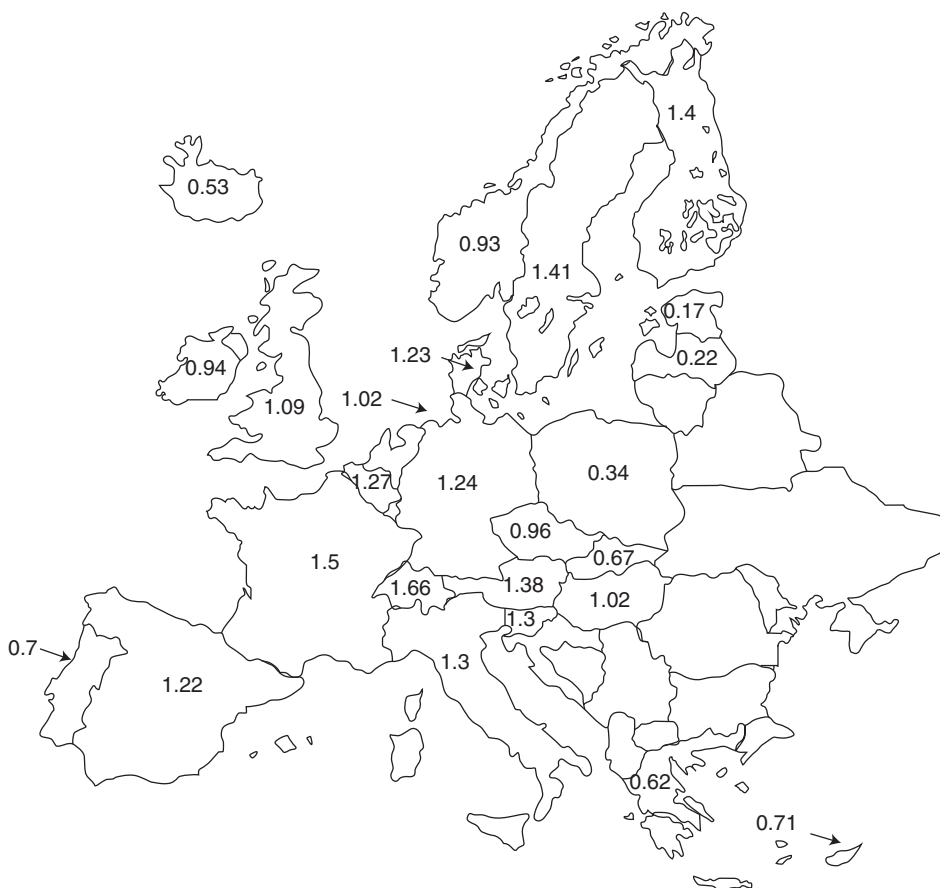
### Sporadic CJD

#### *Epidemiology*

Sporadic CJD is rare, with mortality rates of approximately 1.5 cases per million per annum in systematic national surveys (Fig. 1) (Ladogana et al. 2005). Lower rates in some countries

probably reflect limited case ascertainment, and higher rates in a few smaller countries may indicate that the true mortality rates are higher. However, small changes in annual case numbers may result in fluctuations in mortality in small populations.

Sporadic CJD has been identified worldwide (Will 2014), and the distribution of cases within individual countries or regions is random (Couzens et al. 1997), with no good evidence of space–time clustering to indicate an environmental source of infection. This observation is consistent with case-control studies of risk factors for the development of disease, which have been largely negative, with positive findings likely reflecting methodological biases rather than true biological risk factors (de Pedro Cuesta et al.



**Figure 1.** Mean annual mortality rates for sporadic Creutzfeldt–Jakob disease (sCJD) in Europe (periods of surveillance, 8–21 years).

2012). The exceptions are an increased frequency of sCJD in patients with a history of prior surgery (de Pedro Cuesta et al. 2011), although this is not consistent in all studies (Ward et al. 2008). There is no evidence of an increased risk through working, for example, in medical or paramedical occupations (Alcalde-Cabero et al. 2012), or related to social contact with affected patients. There is strong, but not definitive, evidence that sCJD is not transmitted from person to person through blood transfusion (Dorsey et al. 2009; Puopolo et al. 2011).

The epidemiological evidence strongly suggests that sCJD is not acquired from an external infectious source. This agrees with the favored hypothesis that sCJD develops as a result of a random conversion of normal prion protein to the disease-associated form, which accumulates through autocatalysis and eventually results in neuronal death and the development of clinical disease.

### *Clinical Features and Investigations*

The classical clinical features of sCJD are rapidly progressive dementia, ataxia, and myoclonic involuntary movements (Table 1) (Will 2002).

**Table 1.** Symptoms and signs in sporadic Creutzfeldt–Jakob disease (sCJD) (pathologically confirmed) by codon 129 genotype

Symptoms and signs	MM	MV	VV
	( <i>n</i> = 119) %	( <i>n</i> = 45) %	( <i>n</i> = 32) %
Forgetfulness	98	100	100
Gait disorder	98	93	100
Language disturbance	61	49	44
Behavioral symptoms	54	36	22
Visual impairment	50	31	56
Cognitive impairment	99	100	100
Myoclonus	95	93	91
Ataxia	64	76	94
Spasticity	62	38	44
Akinetic mutism	59	27	22

Data adapted from Chohan (2013).

The evolution of multifocal neurological features over days or weeks distinguishes typical cases of sCJD from more common forms of dementia. However, early diagnosis is difficult because cases may present initially with isolated syndromes such as cerebellar ataxia (Cooper et al. 2006), cortical visual impairment (Cooper et al. 2005), or with acute deficits reminiscent of stroke (McNaughton and Will 1997). The mean duration of illness in sCJD is 4 months, but there are atypical cases with a more protracted clinical course and/or unusual clinical features such as pure cognitive impairment (Brown et al. 1984).

The heterogeneity of clinical presentation is linked to variations in the genotype at codon 129 of the prion protein gene (*PRNP*) and the type of prion protein deposited in the brain. The division of sCJD into six subtypes based on these variables (codon 129 genotypes [MM, MV, and VV] and prion protein types 1 and 2) largely correlates with variations in phenotype, including age at onset of symptoms (Table 2) (Parchi et al. 1999). The MM1 form presents with the classical phenotype and a median age at onset of 66 years, whereas the other forms have atypical clinical features and an earlier age at onset, notably the VV1 subtype.

Specialist investigations contribute to the diagnosis of sCJD. Triphasic periodic complexes on the electroencephalogram (EEG) are virtually diagnostic of sCJD, as these changes occur only rarely in other conditions (Zerr et al. 2000). The sensitivity of this investigation has dropped significantly in recent years, probably because the EEG has largely been replaced by other tests. Magnetic resonance imaging (MRI) shows high signal in the caudate, putamen, and/or cortex on diffusion-weighted imaging (DWI) in perhaps 80% of cases, including some of the atypical subtypes (Fig. 2) (Meissner et al. 2009a). The cerebrospinal fluid (CSF) assay for 14-3-3 protein has limited specificity but is diagnostically useful in the appropriate clinical context (Green et al. 2007). Real-time quaking-induced conversion (RT-QuIC) amplification of CSF prion protein promises to be an important advance in the diagnosis of sCJD because of a remarkably high sensitivity and

**Table 2.** Subtypes of sporadic Creutzfeldt–Jakob disease (sCJD) classified by *PRNP* codon 129 genotype and protease-resistant prion protein (PrP<sup>res</sup>) type

Subtype	Frequency (%)	Median age at onset (years)	Median duration of illness (months)	Typical neuropathological features (see Fig. 4)	Patterns of prion protein (PrP) deposits on immunohistochemistry (see Fig. 5)																												
MM1	57	66	3	Microvacuolar spongiform change: cerebral cortex (frontal and occipital lobes), thalamus, cerebellum	Synaptic, granular																												
MV1	6	73	5			VV1	2	53	10	Microvacuolar spongiform change: cerebral cortex (frontal lobe), entorhinal cortex, basal ganglia	Synaptic, with pale staining	MM2 cortical	7	52	17	Confluent spongiform change: cerebral cortex, entorhinal cortex	Perivacuolar	MM2 thalamic (also known as sporadic fatal insomnia)	<1	53 <sup>a</sup>	16 <sup>a</sup>	Patchy spongiform change: cerebral cortex, entorhinal cortex, cerebellum; marked anterior and medial thalamic gliosis and neuronal loss	Synaptic, granular	MV2	14	65	11	Microvacuolar/confluent spongiform change: cerebral cortex, entorhinal cortex, hippocampus, basal ganglia, thalamus; kuru-type plaques in cerebellar cortex	Kuru plaques in cerebellum; synaptic and plaque-like deposits elsewhere	VV2	14	66	6
VV1	2	53	10	Microvacuolar spongiform change: cerebral cortex (frontal lobe), entorhinal cortex, basal ganglia	Synaptic, with pale staining																												
MM2 cortical	7	52	17	Confluent spongiform change: cerebral cortex, entorhinal cortex	Perivacuolar																												
MM2 thalamic (also known as sporadic fatal insomnia)	<1	53 <sup>a</sup>	16 <sup>a</sup>	Patchy spongiform change: cerebral cortex, entorhinal cortex, cerebellum; marked anterior and medial thalamic gliosis and neuronal loss	Synaptic, granular																												
MV2	14	65	11	Microvacuolar/confluent spongiform change: cerebral cortex, entorhinal cortex, hippocampus, basal ganglia, thalamus; kuru-type plaques in cerebellar cortex	Kuru plaques in cerebellum; synaptic and plaque-like deposits elsewhere																												
VV2	14	66	6	Microvacuolar/confluent spongiform change: cerebral cortex layer 3, hippocampus, basal ganglia, thalamus; cerebellum severely involved, with neuronal loss, gliosis, and atrophy	Synaptic, perineuronal, plaque-like, especially in the cerebellum																												

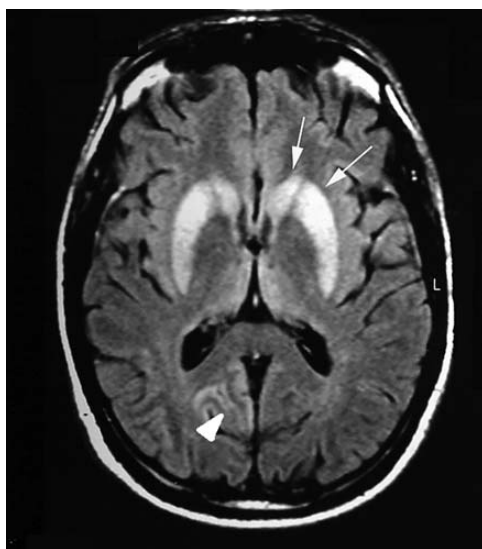
Data from the UK National Creutzfeldt–Jakob Disease Research and Surveillance Unit is adapted from Ironside et al. (2008). Cases with mixed PrP<sup>res</sup> types are not included.

<sup>a</sup>Data derived from a single case.

specificity (Fig. 3) (McGuire et al. 2012). Olfactory mucosa biopsy combined with RT-QuIC has a similar utility, but requires expertise to obtain appropriate specimens (Orrú et al. 2014).

### *Pathology/Protein Biochemistry*

Macroscopic examination of the brain in cases of sCJD usually shows only age-related changes (Ironside et al. 2008). In contrast to most other



**Figure 2.** Magnetic resonance imaging (MRI) brain scan in sporadic Creutzfeldt–Jakob disease (sCJD): Arrows indicate high signal in the caudate, putamen, and occipital cortex.

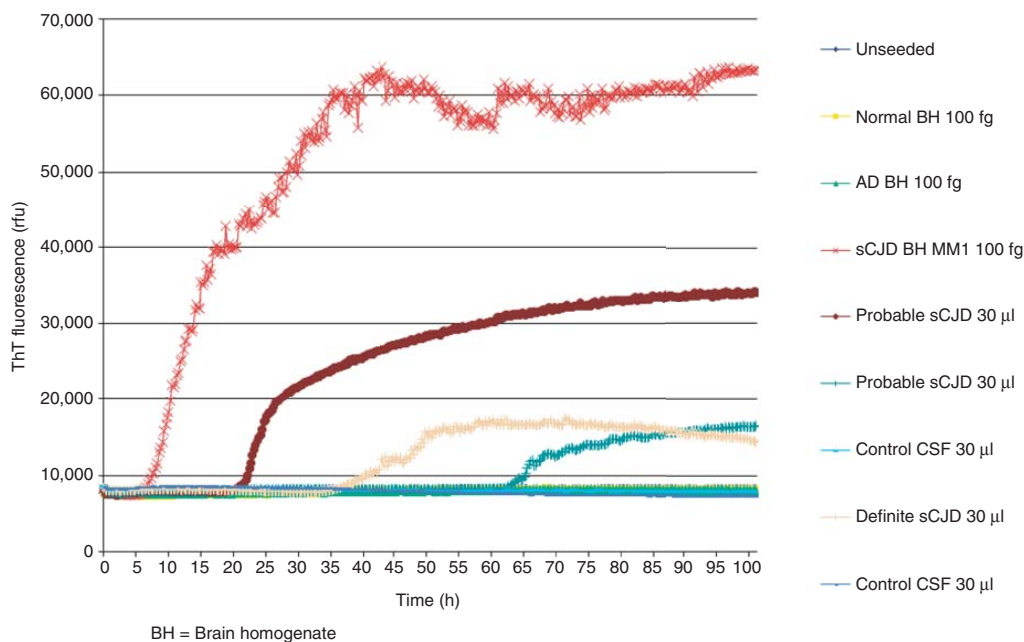
neurodegenerative diseases, the hippocampus is usually spared. Some cases with a long duration of illness show marked cerebral and cerebellar atrophy; in severe cases, this is accompanied by secondary degeneration of the cerebral white matter, referred to as panencephalopathic CJD (Jansen et al. 2009). Cerebellar atrophy, most evident in the superior vermis, is present in some cases of sCJD, particularly the VV2 subtype.

The neuropathology of sCJD is characterized by spongiform change, reactive gliosis involving microglia and astrocytes, and the accumulation of PrP<sup>Sc</sup> (Ironside et al. 2008). These abnormalities vary in severity and distribution in the brain, not only between the different sCJD subtypes but also within a single case (Fig. 4) (Parchi et al. 1996). Spongiform change comprises multiple rounded vacuoles in the gray matter, varying from 2 to 20  $\mu\text{m}$  in diameter in microvacuolar spongiform change found in the MM1/MV1 subtypes to larger vacuoles in confluent spongiform change in the MM2 cortical subtype (Fig. 4) (Parchi et al. 1999). Status spongiosus comprises numerous large, coarse vacuoles in the gray

matter with extensive neuronal loss, severe gliosis, and collapse of the cortical cytoarchitecture, particularly in panencephalopathic sCJD. PrP<sup>Sc</sup> accumulates in various forms in sporadic CJD, for example, synaptic/granular deposits in the MM1/MV1 subtypes, perivacuolar accumulation in the MM2 cortical subtype (Fig. 4), perineuronal accumulation in the VV2 subtype, and kuru-type amyloid plaques in the MV2 subtype (Fig. 5) (Parchi et al. 1999). PrP<sup>Sc</sup> has also been detected in extraneural tissues in sCJD, including the pituitary gland, peripheral nerves, and, as a rare event, in the spleen (Glatzel et al. 2003; Head et al. 2004; Peden et al. 2007).

Unfixed brain tissue homogenates from cases of suspected prion disease can be examined by Western blotting for the presence of PrP<sup>Sc</sup>. Controlled proteolysis of homogenates with enzymes such as proteinase K (PK) digests PrP<sup>C</sup> and results in N-terminal truncation of PrP<sup>Sc</sup>, yielding a protease-resistant fragment known as PrP<sup>res</sup>, which occurs in di-, mono-, and unglycosylated forms (Ironside et al. 2008). In CJD, the unglycosylated form of PrP<sup>res</sup> shows two distinct patterns of electrophoretic mobility, which are termed type 1 and type 2. Type 1 has a relative molecular mass of 21 kDa and a primary PK cleavage site at residue 82, whereas type 2 has a relative molecular mass of 19 kDa and a primary PK cleavage site at residue 97 (Parchi et al. 1997). Accordingly, PrP<sup>res</sup> biochemical types can be subclassified according to differences in the molecular mass of the unglycosylated band (fragment size) and the glycosylation ratio (relative abundance of the three PrP<sup>res</sup> glycoforms); this forms the basis of molecular subtyping in human prion diseases (Fig. 6) (Parchi et al. 1999).

The six subtypes of sCJD, defined according to the *PRNP* codon 129 genotype and PrP<sup>res</sup> type (MM1/MV1, MM2 cortical, MM2 thalamic, MV2, VV1, and VV2), have characteristic differences in their neuropathological features (Figs. 4 and 5) (Parchi et al. 1999). Table 2 summarizes the predominant clinical and neuropathological features of these sCJD subtypes. However, not all sCJD cases exhibit these characteristic features, and atypical cases are recog-



**Figure 3.** Real-time quaking-induced conversion (RT-QuIC) on cerebrospinal fluid (CSF) in sporadic Creutzfeldt–Jakob disease (sCJD): relative fluorescence with time.

nized in terms of both clinical and neuropathological findings (Ironside et al. 2005). Recently, the co-occurrence of mixed PrP<sup>res</sup> types (e.g., types 1 and 2) in individual cases of sCJD has been recognized in ~30% of cases, which has necessitated review of the classification system described above (Parchi et al. 2009); the variability of phenotype in sCJD may also be linked to different causative prion strains (Bishop et al. 2010; Moda et al. 2012).

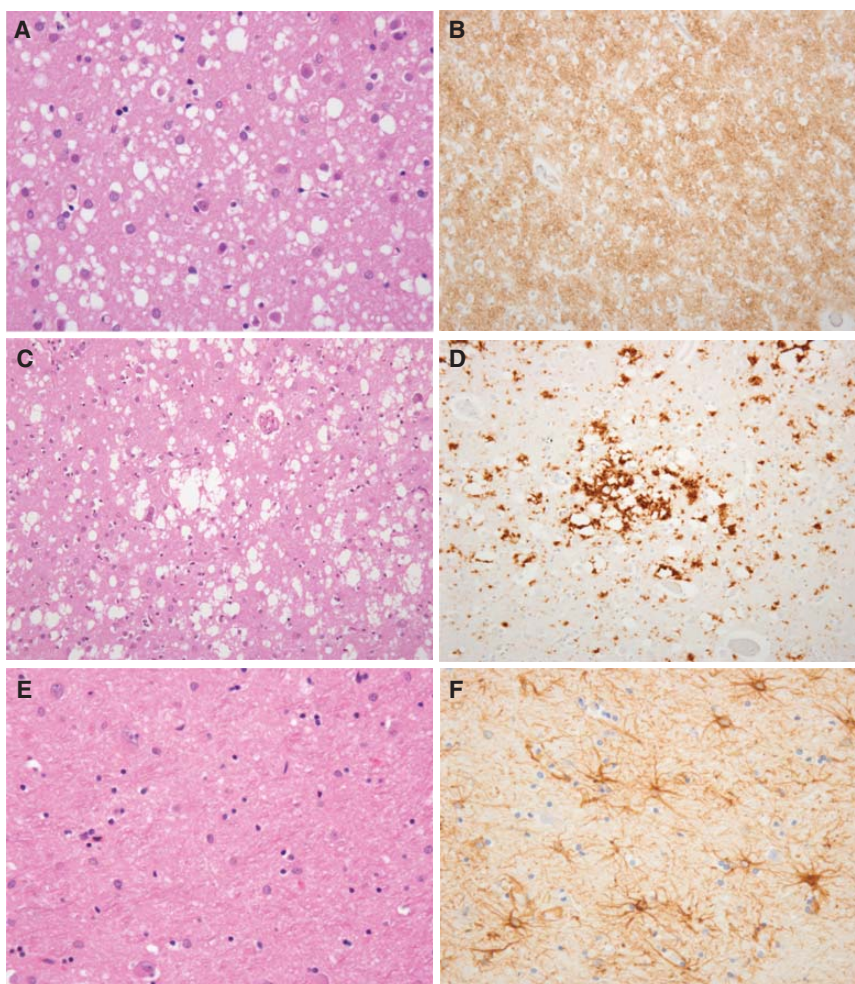
### Variably Protease-Sensitive Prionopathy

Variably protease-sensitive prionopathy (VPSPr) is a recently identified human prion disease, first described in the United States in 2008 (Gambetti et al. 2008). Cases have also been identified in Europe (Head et al. 2013). VPSPr is an idiopathic disorder; patients do not appear to have any risk factors for acquired prion disease, and no mutations in the *PRNP* coding sequence have been identified in the cases described to date. VPSPr occurs in all three *PRNP* codon 129 genotypes but, in contrast to sCJD, most cases have occurred in individuals carry-

ing the VV genotype, followed by the MV and MM genotypes (Zou et al. 2010).

The clinical features of VPSPr are less stereotyped than those of sCJD; most patients are in the seventh decade or older, with a lengthy clinical history (usually >2 years) in which a variety of movement disorders, extrapyramidal signs, cerebellar ataxia, and cognitive impairment occur, but rapidly progressive dementia is uncommon (Zou et al. 2010). Clinical diagnostic criteria for VPSPr remain to be defined, and the precise incidence of this disorder is uncertain; retrospective review in the United Kingdom by the National CJD Research and Surveillance Unit. The National CJD Research and Surveillance Unit suggests that it is much rarer than sCJD, but is likely to be under-ascertained (Head et al. 2013).

VPSPr is a spongiform encephalopathy, with intermediately sized vacuoles in the gray matter of the cerebral cortex, basal ganglia, thalamus, and cerebellar cortex (Gambetti et al. 2008). However, the characteristic neuropathological feature is the presence of microplaques that often appear in a “target” arrangement and are particularly common in the cerebellar mo-

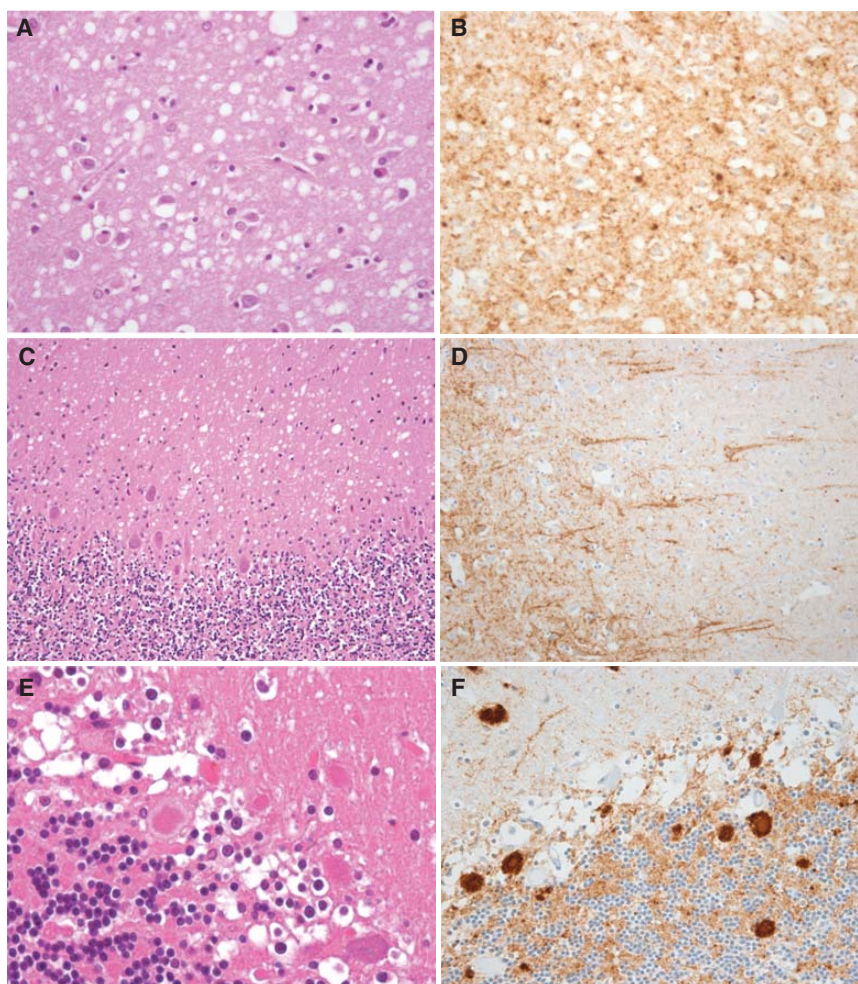


**Figure 4.** Neuropathology of sporadic Creutzfeldt–Jakob disease (sCJD) subtypes: (A,B) MM1/MV1; (C,D) MM2; and (E,F) sporadic fatal insomnia. (A) The frontal cortex in the MM1 and MV1 subtypes shows microvacuolar spongiform change. Hematoxylin and eosin,  $\times 40$ . (B) PrP accumulates in the cerebral cortex in the MM1/MV1 subtypes in a diffuse granular/synaptic pattern. 12F10 antibody,  $\times 40$ . (C) The frontal cortex in the MM2 cortical subtype shows confluent spongiform change. Hematoxylin and eosin,  $\times 20$ . (D) PrP accumulates in the cerebral cortex in the MM2 cortical subtype in a dense perivacuolar pattern. 12F10 antibody,  $\times 20$ . (E) The thalamus in sporadic fatal insomnia (MM2 thalamic subtype) exhibits severe neuronal loss without significant vacuolation. Hematoxylin and eosin,  $\times 40$ . (F) Marked thalamic gliosis in sporadic fatal insomnia is demonstrated with an antibody to glial fibrillary acidic protein,  $\times 40$ .

lecular layer, particularly in the *PRNP* codon 129 VV genotype (Fig. 7) (Zou et al. 2010). Microplaques may also occur in the thalamus, basal ganglia, hippocampus, and cerebral cortex. Immunohistochemistry for PrP shows patchy diffuse labeling in the cerebral cortex, whereas the microplaques show more intense labeling and are periodic acid–Schiff (PAS)

positive. These neuropathological features are quite distinct from those of the sCJD VV1 and VV2 subtypes (Fig. 5) (Parchi et al. 1999). The presence of the M129 allele modifies the neuropathology of VPSPr, with larger plaques appearing in the MM genotype (Zou et al. 2010).

The defining feature of VPSPr that gives this disorder its name is the presence of PrP<sup>Sc</sup> in the

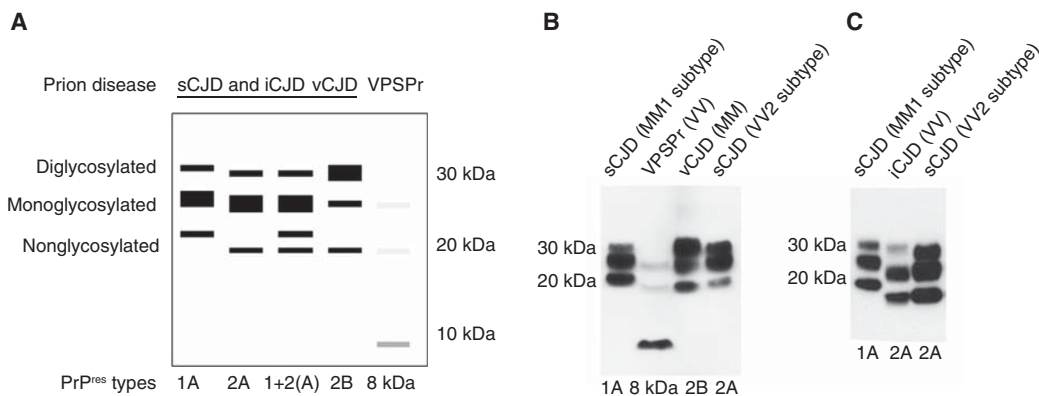


**Figure 5.** Neuropathology of sporadic Creutzfeldt–Jakob disease (sCJD) subtypes: (A,B) VV1; (C,D) VV2; (E,F) MV2. (A) Spongiform change in the temporal cortex in the VV1 subtype has vacuoles intermediate in size between the MM1 and MM2 subtypes. Hematoxylin and eosin,  $\times 40$ . (B) Prion protein (PrP) accumulates in the temporal cortex in a patchy coarse granular pattern in the VV1 subtype. 12F10 antibody,  $\times 40$ . (C) Spongiform change in the VV2 subtype is most marked in the molecular layer of the cerebellum. Hematoxylin and eosin,  $\times 20$ . (D) PrP accumulates in the frontal cortex in a perineuronal/granular pattern in the VV2 subtype. 12F10 antibody,  $\times 20$ . (E). The pathological hallmark of the MV2 subtype is the kuru-type plaque in the cerebellum, composed of a dense amyloid core with paler peripheral fibrils. Hematoxylin and eosin,  $\times 40$ . (F) PrP accumulates in the kuru-type plaques and in a granular/synaptic pattern in the cerebellum of the MV2 subtype. 12F10 antibody,  $\times 40$ .

brain that is poorly resistant to PK digestion, yielding a characteristic 8-kDa amino- and carboxy-terminally truncated band in Western blots, which is often accompanied by a faint “ladder” of bands extending into the 18–30 kDa range (Fig. 6) (Gambetti et al. 2008). Some cases of VPSPr also show an sCJD-like

type 2A pattern in the cerebellum, suggesting molecular overlap with sCJD (Head et al. 2013). Recent studies have indicated that VPSPr is poorly transmissible to transgenic mice, with transmission characteristics that are markedly different from those of sCJD (Diack et al. 2014; Notari et al. 2014).





**Figure 6.** Western blot for protease-resistant prion protein (PrP<sup>res</sup>) in sporadic, iatrogenic, and variant Creutzfeldt–Jakob disease (CJD) as well as in variably protease-sensitive prionopathy (VPSPr). (A) Schematic representation of the PrP<sup>res</sup> types recognized to characterize sporadic CJD (sCJD), iatrogenic CJD (iCJD), variant CJD (vCJD), and VPSPr brain tissue. The typing scheme has two component parts, the mobility of the bottom (nonglycosylated) fragment (type 1 at ~21 kDa and/or type 2 at ~19 kDa) and glycosylation site occupancy (A, in which the *middle*, monoglycosylated band predominates, or B, in which the *top*, diglycosylated band predominates). (B) Western blot analysis of brain tissue from the two most common subtypes of sCJD (MM1 and VV2), vCJD, and VPSPr. The VPSPr lane was loaded with 10 times the amount of brain homogenate loaded in the CJD lanes. (C) Western blot analysis of brain tissue from a case of human growth hormone (hGH) iCJD (VV), flanked by samples of sCJD of the MM1 and VV2 subtypes. Typing of the sample is designated *below* each lane.

## ACQUIRED HUMAN PRION DISEASES

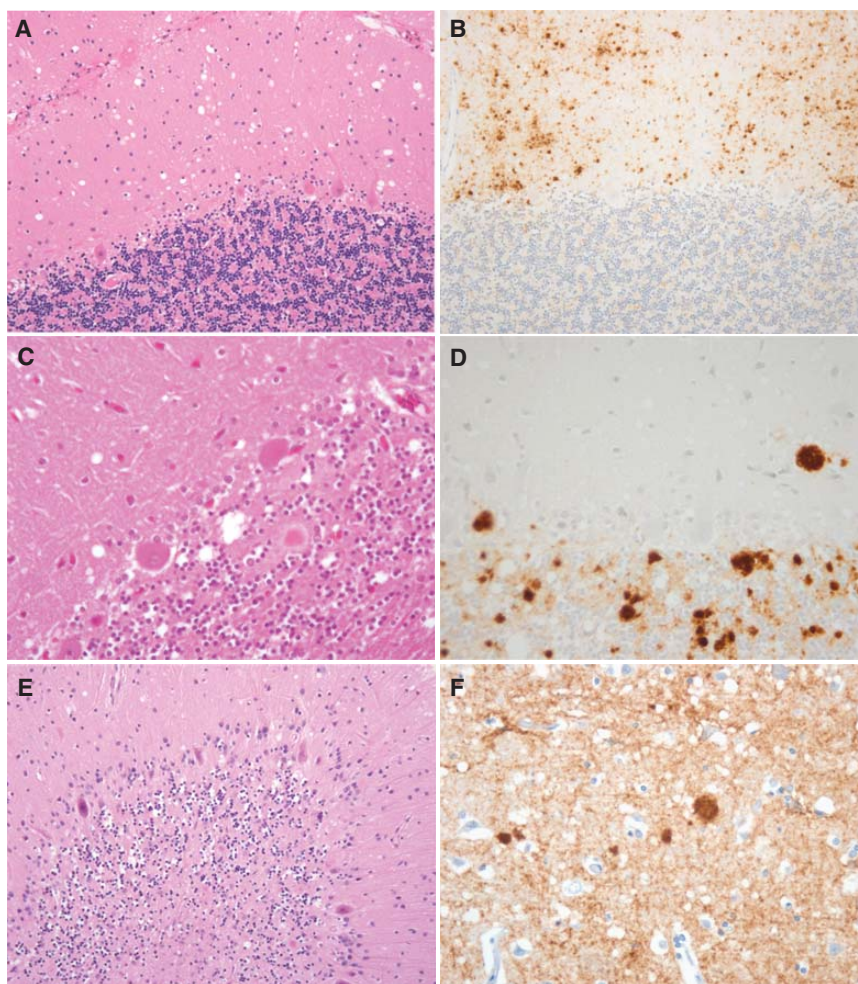
### Kuru

Kuru was first reported in the 1950s as a common neurological disorder occurring in the isolated Fore tribe in the Eastern Highlands of Papua New Guinea (for review, see Liberski et al. 2012). It occurred most frequently in women and children of both sexes as a progressive ataxic syndrome with dysarthria, dysphagia, and tremor followed by pyramidal and extrapyramidal motor dysfunction. Cognitive impairment and dementia were uncommon, but emotional lability occurred in the later stages of the illness. The mean duration of illness in kuru was approximately 12 months.

The cause of kuru was unknown until the neuropathological changes were noted to resemble those of scrapie, a transmissible spongiform encephalopathy of sheep and goats (Hadlow 1959). Kuru was experimentally transmitted to primates in 1966, thereby becoming the first proven transmissible spongiform encephalopathy of humans (Gajdusek et al. 1966).

Kuru occurred as an epidemic within the Fore tribe; its transmission was associated with ritualistic endocannibalism in the tribe, during which the brain was most often handled or consumed by women and children (Liberski et al. 2012). It has been proposed that kuru originated from the consumption of brain tissue from a tribe member who had died with sCJD; this has been supported by the findings of transmission studies of kuru and sCJD to transgenic and wild-type mice (Wadsworth et al. 2008). Kuru declined after this ritual was discouraged in the 1960s and is now extinct. The youngest patient with kuru was 5 years old, and the mean age at death in the 1950s was approximately 49 years. The age at death increased with time, and the final patients in the early years of the 21st century were >60 years old, with incubation periods of >40 years (Collinge et al. 2008). Kuru occurred in patients of all PRNP codon 129 genotypes; heterozygotes appear to have had significantly longer incubation periods than homozygotes (Collinge et al. 2006).

The neuropathology of kuru resembled that of sCJD (Neumann et al. 1964); a key feature in



**Figure 7.** Neuropathology: (A,B) variably protease-sensitive prionopathy (VPSPr); (C,D) kuru; and (E,F) iatrogenic Creutzfeldt–Jakob disease (iCJD). (A) The cerebellar molecular layer in VPSPr shows patchy spongiform change. Hematoxylin and eosin,  $\times 20$ . (B) Prion protein (PrP) accumulates in the cerebellar cortex in numerous microplaques, one of the pathological hallmarks of VPSPr. 12F10 antibody,  $\times 20$ . (C) The granular layer of the cerebellum in kuru often contains characteristic plaques, with a dense amyloid core and pale peripheral fibrils. Hematoxylin and eosin,  $\times 40$ . (D) PrP accumulates in the cerebellar plaques in kuru and in a patchy distribution in the granular layer. KG9 antibody,  $\times 20$ . (E) The cerebellum in iCJD in hGH recipients is atrophic, with marked neuronal loss and gliosis. Hematoxylin and eosin,  $\times 20$ . (F) PrP accumulates in the frontal cortex in iCJD in an hGH recipient in a plaque-like pattern with widespread granular/synaptic positivity. 12F10 antibody,  $\times 40$ .

many cases was the presence of amyloid plaques with a solid core and radiating fibrils in the cerebellar cortex, subsequently termed “kuru plaques” (Fig. 7). Spongiform change occurred in a variable distribution in the cerebral cortex, basal ganglia, thalamus, and cerebellum. Cerebellar involvement was often severe, with significant neuronal loss and gliosis and secondary

white matter degeneration. The neuropathological features appear to have been influenced by the *PRNP* codon 129 genotype, with kuru-type plaques generally associated with the MV genotype. Only very limited information is available on the PrP<sup>res</sup> isoforms in the brain in kuru, which are reported to resemble those of the type 2 isoform found in sCJD (Brandner et al. 2008).

## Iatrogenic CJD

### Epidemiology

The occurrence of CJD in relatively small cohorts of individuals exposed to human tissues in the course of medical treatment provides strong circumstantial evidence of iatrogenic transmission of this condition. CJD has occurred in over 200 cases treated with human pituitary hormones and similar numbers of recipients of human dura mater grafts (Brown et al. 2012). There have also been a few cases of CJD causally linked to corneal grafts, depth electrodes, and contaminated neurosurgical instruments (Table 3). The latter iatrogenic cases are largely historical, but cases linked to human growth hormone (hGH) and human dura mater grafts continue to occur, reflecting extended incubation periods of up to 42 and 30 years, respectively, although the numbers of such cases are gradually declining overall.

The presumption is that tissues from sCJD cases entered the production process and that pooling of pituitary glands or dura mater grafts led to dissemination of infection. The incidence of hGH CJD varies by country, probably in relation to the level of contamination entering the production process, whereas the rates for dura mater CJD likely reflect the frequency of use of this material in neurosurgery. Recombinant pituitary hormones and synthetic or autologous grafts have largely replaced human-derived treatments, and new iatrogenic exposures through these exposures are unlikely to occur.

### Clinical Features/Investigations

The clinical presentation in iatrogenic CJD (iCJD) varies according to the route of exposure. Infection in or adjacent to the brain (e.g., via neurosurgical instruments or dura mater grafts) leads to a clinical phenotype similar to sCJD with a rapidly progressive dementia often associated with ataxia and myoclonus. Following peripheral exposure (e.g., through injections of hGH), there is a progressive ataxic syndrome, and cognitive impairment is a less prominent and late feature, if it occurs at all

**Table 3.** Causes of iatrogenic Creutzfeldt–Jakob disease (iCJD)

Source of infection	Number of cases worldwide
Surgical instruments	4
Electroencephalogram (EEG)	2
Corneal transplant	2
Gonadotrophin	4
Growth hormone	226
Dura mater grafts	228
Packed red blood cells	3

Data adapted from Brown et al. (2012).

(Rudge et al. 2015). The mean survival in hGH CJD is approximately 12 months, whereas with other forms of iCJD, the duration of illness is relatively short and similar to sCJD.

Although there is limited data, the investigations in iCJD, including EEG, MRI brain scan, and CSF 14-3-3, have a similar sensitivity and specificity as in sCJD. The diagnosis of iCJD rests on seeking a history of potential risk factors in suspected cases of CJD or in individuals presenting with a progressive ataxic syndrome, particularly in younger patients.

In Caucasian populations, homozygosity at codon 129 of *PRNP* increases the risk of iCJD. In France, hGH recipients with *PRNP* heterozygosity have a prolonged incubation period before the onset of iCJD (Brandel et al. 2003), whereas in the United Kingdom, the longest incubation periods occur in *PRNP* methionine homozygotes (Rudge et al. 2015), raising the possibility that different strains of sCJD were responsible for the cases of iCJD in hGH recipients in the United Kingdom and France.

### Pathology/Protein Biochemistry

The neuropathology of iCJD generally resembles that of sCJD, which is perhaps not surprising because the sCJD agent is the likely source of infection in most cases. As in sCJD, the neuropathological features are influenced by the patient's *PRNP* codon 129 genotype and the PrP<sup>res</sup> type identified on Western blotting of brain homogenates (Fig. 6) (Meissner et al. 2009b). However, there are some findings that seem to

be unique to iCJD: iCJD in hGH recipients is often accompanied by severe cerebellar pathology with cerebellar cortical atrophy (Fig. 7), the degree of which is usually proportional to the duration of the clinical illness (Ironside et al. 2008). It is uncertain whether this cerebellar involvement reflects the subcutaneous/intramuscular route of CJD infection in these patients and/or the combination of recipient *PRNP* codon 129 genotype and the strain of the infectious agent. A recent study of eight cases of iCJD in hGH recipients in the United Kingdom found evidence of A $\beta$  accumulation as cerebral amyloid angiopathy and/or diffuse A $\beta$  plaques in the cerebral cortex in four cases, raising the possibility of human transmission of A $\beta$  by seeding from A $\beta$  aggregates that occur in the pituitary gland in Alzheimer's disease (Jau-muktane et al. 2015).

In human dura mater graft recipients in Japan, a group of cases contained florid plaques in the brain, without any other evidence of variant CJD-like pathology (Yamada et al. 2009). In the United Kingdom, most cases of iCJD in human dura mater graft recipients have type 1 PrP<sup>res</sup> in the brain, but in hGH recipients, there is a predominance of type 2 PrP<sup>res</sup> (Heath et al. 2006). Occasional cases with admixtures of type 1 and type 2 PrP<sup>res</sup> have also been identified (Ironside et al. 2008).

## Variant CJD

### *Epidemiology*

Variant CJD (vCJD) was identified in 1996 as a novel human prion disease, and its occurrence in the United Kingdom led to the hypothesis that this disease was caused by transmission of bovine spongiform encephalopathy (BSE) to the human population (Will et al. 1996). Subsequent research, including transmission studies in wild-type (Bruce et al. 1997) and transgenic mice (Hill et al. 1997a; Scott et al. 1999), provides compelling evidence that vCJD is indeed a zoonosis, likely caused by prior dietary exposure to high-titer bovine tissues in the human food chain (Ward et al. 2006).

The extensive exposure of the UK population to BSE led to concerns that there might be a

large epidemic of vCJD, but the outbreak in the country peaked in 2000 and has subsequently declined. All tested definite and probable cases of vCJD worldwide (211/228) have had a methionine homozygous genotype at codon 129 of *PRNP*, but a confirmed case has recently been identified in the United Kingdom with a heterozygous genotype at codon 129 of *PRNP*, raising the possibility of a further outbreak (Fig. 8). The disparity between the high level of infection in the human food chain and the limited outbreak of vCJD may be related to a significant species barrier between bovines and humans, with a high threshold dose for infection.

Limited numbers of cases of vCJD have been identified in other countries (Table 4) as a result of exposure to BSE, probably through UK exports of bovines and bovine derivatives. However, some cases are likely attributable to residence in the United Kingdom during the risk period 1980–1996, with the disease developing after moving to a new country of residence. The numbers of new cases of vCJD in non-UK countries have also declined, and fears of a large epidemic of vCJD have receded.

The incubation period in vCJD is unknown in individual cases, but a mean of 15 years has been suggested by mathematical models (Valle-ron et al. 2001) and extrapolation from descriptive epidemiological data. This estimate indicates that it may be some years before the full extent of the vCJD outbreak can be determined with confidence, not least because of the possibility of further cases in codon 129 heterozygotes.

### *Clinical Features/Investigations*

Variant CJD affects younger age groups than sCJD, with a mean age at death of 30 years (Heath and Will 2008). Thirty-four of the cases in the United Kingdom were under the age of 20 years at onset, and a case with an onset at 11 years has been reported from Portugal (Barbot et al. 2010). The reason for this age distribution is uncertain but may relate to patterns of dietary exposure varying with age (Cooper and Bird 2002) or age-related susceptibility (Boelle et al. 2003; St Rose et al. 2006).

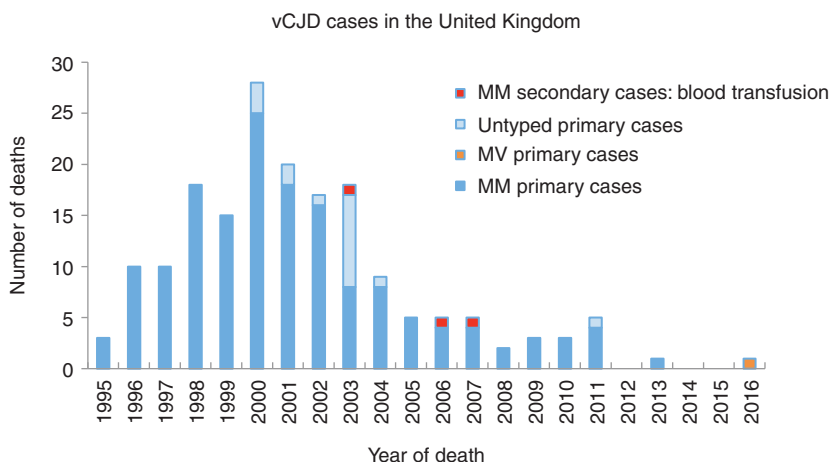


Figure 8. Epidemiologic curve of variant Creutzfeldt–Jakob disease (vCJD) in the United Kingdom.

The initial symptoms of vCJD are predominantly psychiatric for a mean of 6 months before progression to a neurological disorder typified by progressive ataxia and cognitive impairment associated with involuntary movements, including dystonia, chorea, and myoclonus (Table 5) (Zeidler et al. 1997a,b). The terminal stages are similar to sCJD, with accu-

mulating neurological deficits leading to helplessness and death, often resulting from intercurrent infection. The median duration of illness is 14 months.

Diagnosis of vCJD may be impossible in the early stages, although a combination of depression and painful sensory symptoms may suggest the condition, particularly in a younger individ-

Table 4. Variant Creutzfeldt–Jakob disease (vCJD) in countries across the world

Country	Total number of primary cases (number alive)	Total number of secondary cases: blood transfusion (number alive)	Residence in the United Kingdom >6 months during period 1980–1996
United Kingdom	175 (0)	3 (0)	178 <sup>a</sup>
France	27 (0)	–	1
Republic of Ireland	4 (0)	–	2
Italy	2 (0)	–	0
United States	4 <sup>b</sup> (0)	–	2
Canada	2 (0)	–	1
Saudi Arabia	1 (0)	–	0
Japan	1 <sup>c</sup> (0)	–	0
Netherlands	3 (0)	–	0
Portugal	2 (0)	–	0
Spain	5 (0)	–	0
Taiwan	1 (0)	–	1

<sup>a</sup>Case 178 from the United Kingdom was heterozygous at codon 129 of the *PRNP* gene.

<sup>b</sup>The third U.S. patient with vCJD was born and raised in Saudi Arabia and has lived permanently in the United States since late 2005. According to the U.S. case report, the patient was most likely infected as a child when living in Saudi Arabia. In the fourth U.S. patient, the history indicated that exposure to infection most likely occurred prior to moving to the United States.

<sup>c</sup>The case from Japan had resided in the United Kingdom for 24 days during the period 1980–1996.

**Table 5.** Symptoms and signs in variant Creutzfeldt–Jakob disease (vCJD)

Symptoms and signs	Percentage
Early psychiatric symptoms	92
Painful sensory symptoms	63
Visual symptoms	50
Delusions	33
Dementia	100
Ataxia	97
Chorea/dystonia/myoclonus	94
Spasticity	45

Data adapted from Heath and Will (2008).

ual. Six cases over the age of 55 years have been identified in the United Kingdom, but only two were diagnosed in life, indicating the importance of a high index of suspicion of vCJD diagnosis regardless of age.

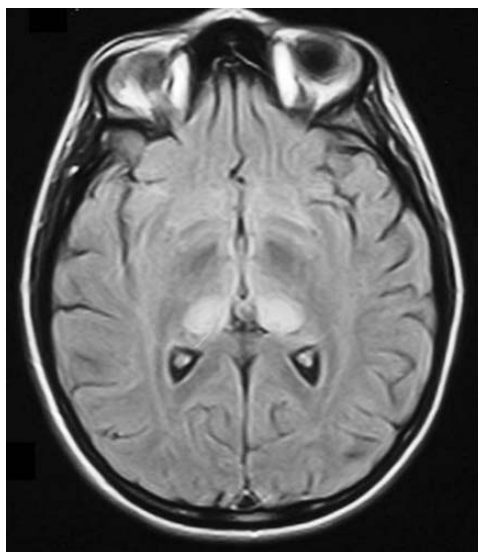
The MRI scan is the most helpful investigation in vCJD, showing high signal in the posterior thalamus, the “pulvinar sign,” on fluid-attenuated inversion recovery (FLAIR) and/or DWI in >90% of cases (Fig. 9) (Collie et al. 2003). The recent heterozygote case had a clinical phenotype similar to previous cases, but the MRI scan showed appearances suggestive of sporadic CJD. The EEG may be normal even after the evolution of neurological signs and shows periodic triphasic complexes only rarely and in the terminal stages of the illness (Binelli et al. 2006; Yamada 2006). The CSF 14-3-3 is positive in approximately half the cases (Green et al. 2001), whereas the RT-QuIC is uniformly negative in vCJD using current techniques. Tonsil biopsy can demonstrate positive prion protein in follicular dendritic cells (Hill et al. 1997b), but this procedure carries risks and may be best reserved for cases in which the MRI scan is negative.

The search for a blood test to confirm the presence of infection in affected patients or in individuals in the incubation period of infection has been a major research objective, and although one such test shows clear promise (Edgeworth et al. 2011), no fully validated blood test is yet available. Recent evidence suggests that the protein-misfolding cyclic amplification (PMCA) technique has the potential to provide a diagnostic test in vCJD urine (Moda

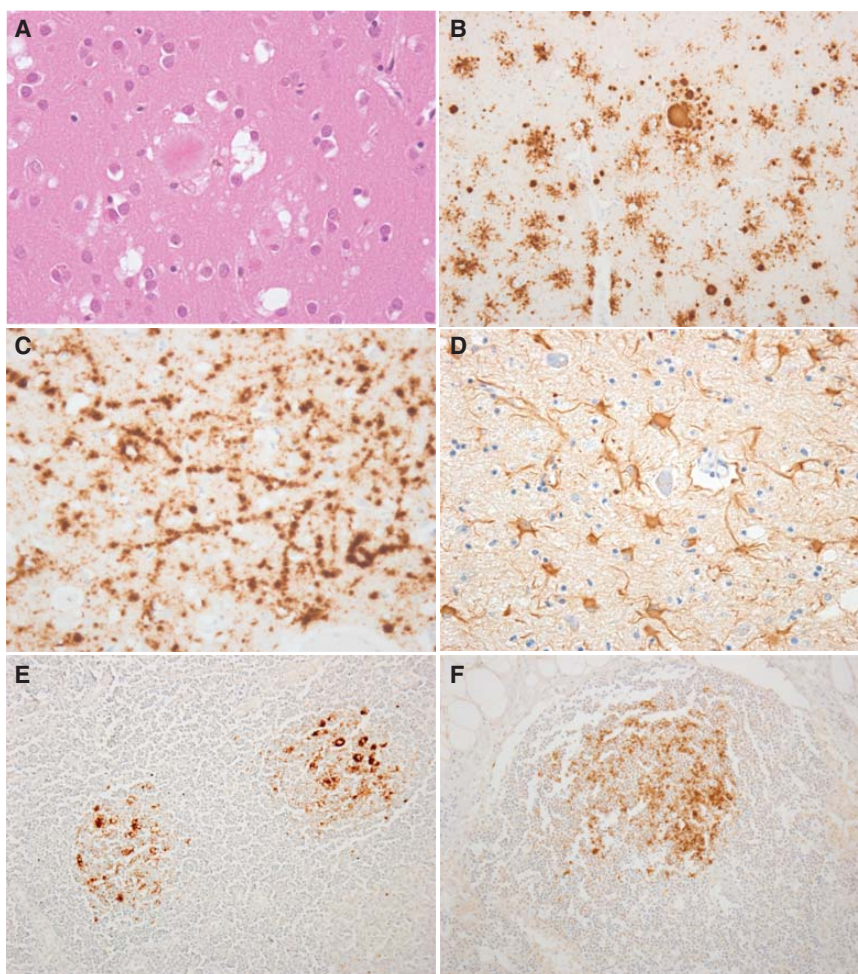
et al. 2014), but this is based on preliminary data, and whether either of these tests would be sufficiently sensitive to detect preclinical cases of vCJD is uncertain.

### *Pathology/Protein Biochemistry*

The neuropathology of vCJD is stereotyped and markedly different from sCJD and iCJD. The most striking and characteristic feature is the presence of large numbers of florid plaques in the cerebral cortex and cerebellar cortex, composed of a central eosinophilic amyloid core with radiating linear amyloid fibrils surrounded by a corona of spongiform change (Fig. 10) (Will et al. 1996). Spongiform change is present to a variable extent in the cerebral cortex, cerebellum, and thalamus, but is most marked in the caudate nucleus and putamen. The thalamus also shows severe neuronal loss and gliosis in the posterior nuclei, particularly the pulvinar, corresponding to the abnormalities identified in this region of the brain on MRI (Collie et al. 2003). Immunohistochemistry for prion protein shows intense labeling of the florid plaques in the cerebral and cerebellar cortex, along with numerous smaller cluster



**Figure 9.** Magnetic resonance imaging (MRI) brain scan in variant Creutzfeldt–Jakob disease (vCJD) showing bilateral pulvinar high signal.



**Figure 10.** Neuropathology of variant Creutzfeldt–Jakob disease (vCJD) and subclinical vCJD infection. (A) The pathological hallmark of vCJD in the frontal cortex is the florid plaque, composed of a dense amyloid core with pale radiating fibrils surrounded by spongiform change. Hematoxylin and eosin,  $\times 40$ . (B) Prion protein (PrP) accumulates in the florid plaques in vCJD and in numerous smaller clusters of plaques and amorphous deposits. 12F10 antibody,  $\times 20$ . (C) In the basal ganglia in vCJD, PrP accumulates in a linear periaxonal pattern. 12F10 antibody,  $\times 40$ . (D) The pulvinar in vCJD exhibits severe neuronal loss and gliosis, with numerous large reactive astrocytes. Glial fibrillary acidic protein antibody,  $\times 40$ . (E) PrP accumulates in the follicular dendritic cells within the lymphoid follicles of the tonsil in vCJD. 12F10 antibody,  $\times 20$ . (F) PrP accumulates in the follicular dendritic cells of a cervical lymph node in a patient (*PRNP* codon 129 MV genotype) who died with an asymptomatic vCJD infection following a contaminated red blood cell transfusion. 12F10 antibody,  $\times 20$ .

plaques that are not present on routine stains, and small amorphous “feathery” deposits of PrP around small capillaries and neurons (Fig. 9) (Ironsides et al. 2008). Small numbers of florid plaques have also been identified in occasional cases of iCJD associated with dura mater grafts in Japan, but these cases do not

exhibit any of the other neuropathological features of vCJD as described above (Yamada et al. 2009).

Variant CJD is unique among human prion diseases in that the accumulation of PrP<sup>res</sup> in lymphoid tissues outside the CNS is readily detected by immunohistochemistry, paraffin-em-

bedded blot, or Western blot analysis (Head et al. 2004). PrP<sup>res</sup> accumulates in follicular dendritic cells within lymphoid follicles and has also been detected in peripheral autonomic ganglia (Fig. 9). This has enabled the use of tonsil biopsy as a diagnostic tool for vCJD in selected patients (Hill et al. 1999). In one case from the United States with a lengthy clinical history, PrP<sup>res</sup> was detected in a wider range of tissues, including skeletal muscle and skin following autopsy (Notari et al. 2010).

Western blot analysis of the brain in vCJD shows a uniform single PrP<sup>res</sup> type (type 2B) with a glycoform profile in which the diglycosylated fragment predominates. This finding is in contrast to other forms of human prion disease (see Fig. 6) (Head and Ironside 2012). A similar PrP<sup>res</sup> isoform is present in lymphoid tissues in vCJD, including tonsil, thymus, spleen, lymph nodes, and gut-associated lymphoid tissues (Head et al. 2004). This PrP<sup>res</sup> isoform is similar to that observed on Western blots in cattle with BSE and in other species infected with BSE, including antelopes and cats (Collinge et al. 1996). Several independent laboratories have agreed that the strain of the transmissible agent in vCJD is similar to that for BSE, but is different from those identified in cases of sCJD (Bruce et al. 1997; Scott et al. 1999).

### *Transfusion Transmission*

The pathogenesis of vCJD is distinct from other human prion diseases, as there are significant levels of infectivity in peripheral tissue, particularly in the lymphoreticular system (Bruce et al. 2001). This observation led to concerns that, in contrast to sCJD, blood transfusion might pose a risk of onward transmission of vCJD, and a look-back study has identified three cases of vCJD with a history of receiving a blood transfusion donated by individuals who themselves developed vCJD (Hewitt et al. 2006). The interval from the transfusion to the onset of symptoms in the cases was 7–9 years, and the period prior to clinical signs in the donors was 1–3 years. In addition, an individual who received such a transfusion and died of intercurrent illness was found to have positivity for prion pro-

tein in spleen and a lymph node, indicating sub-clinical infection (Fig. 10) (Peden et al. 2004). This individual was a PRNP codon 129 heterozygote. A case of a patient with hemophilia with positivity for prion protein in one spleen sample raises the possibility that plasma products may transmit vCJD (Peden et al. 2010).

The occurrence of four infections in the cohort of 34/67 transfusion recipients who survived for at least 5 years from the transfusion indicates that this route of infection is relatively efficient. Laboratory transmission studies suggest that the vCJD prion strain and the associated PrP<sup>res</sup> subtype have not been altered significantly following transfusion transmission (Bishop et al. 2008) or through passage in a PRNP codon 129 heterozygous host (Bishop et al. 2013).

### *Prevalence Studies*

To date, 229 cases of vCJD have been identified worldwide, with 177 occurring in the United Kingdom. Given the likely large exposure of the UK population to the BSE agent via the food chain in the 1980s and 1990s, there is ongoing concern about the numbers of individuals in the country who are infected with BSE and currently asymptomatic but may develop vCJD in the future. In the absence of a screening test for vCJD infection, UK public health concerns also remain over the safety of blood transfusion following four reports of the transmission of vCJD infectivity by packed red blood cell transfusions (see above). To address these concerns, a number of tissue-based studies have been performed using immunohistochemistry to detect abnormal PrP accumulation in lymphoid tissues in appendix and tonsil specimens. These specimens were gathered from hospital pathology department archives and were from UK patients with appendicitis or tonsillitis who were otherwise normal. The first of these studies was reported in 2004, when three of 12,674 specimens tested were positive, giving a prevalence of 237 per million for asymptomatic vCJD infection, with a wide confidence interval (Hilton et al. 2004). The most recent and largest of these studies published in 2013 examined 32,441 appendix



samples from individuals born in birth cohorts from 1941 to 1960 and 1961 to 1985. Of these, 16 cases from both cohorts were found to be positive, giving a prevalence of asymptomatic vCJD infection in the UK population of 493 per million, or approximately one in 2000, with a wide confidence interval (Gill et al. 2013). Interestingly, two of the three positive cases in the first study were valine homozygotes at *PRNP* codon 129 (Ironsides et al. 2006), and all three *PRNP* codon 129 genotypes were represented in the 16 positive cases in the 2013 study, with predominance of the VV genotype (Gill et al. 2013).

These findings suggest that all three *PRNP* codon 129 genotypes are susceptible to vCJD infection and may develop vCJD in the future after an unknown incubation period, during which time they could represent a source of secondary infection to the rest of the UK population. At present, although a number of groups are working on a blood test for vCJD and other human prion diseases, none of the techniques currently under development have yet been demonstrated to detect asymptomatic infections in humans, although this can be achieved in animal models (Edgeworth et al. 2011; Lacroix et al. 2014). It is therefore unlikely that the most recent estimate for the prevalence of asymptomatic vCJD infection in the United Kingdom will be refined and made more accurate in the near future.

## CONCLUDING REMARKS

Much remains to be discovered about the origins of sporadic human prion diseases, which have been variously suggested to be attributable to random stochastic events resulting in PrP misfolding in the brain, somatic mutation of the *PRNP* gene coding sequence, or perhaps as a consequence of an acquired (but undetected) infection from an unknown source (Colby and Prusiner 2011; de Pedro Cuesta et al. 2014). It is challenging to model these various scenarios experimentally; therefore, ongoing epidemiological studies will be required to help address these questions. The recognition that other more common neurodegenerative diseases are associated with the accumulation of other mis-

folded proteins in the CNS has led to the proposal that prion-like mechanisms may also be responsible for these disorders (Prusiner 2013); this is supported by the recent evidence of A $\beta$  seeding in the brains of hGH recipients who developed iCJD.

The subclassification of sCJD into at least six subtypes has reinforced the major influence of host (*PRNP* codon 129 genotype) and agent (PrP<sup>res</sup> types) factors that determine the clinical and pathological phenotypes in this disorder, which is challenging to diagnose in the rarer subtypes or in atypical cases (Head and Ironsides 2012; Kovacs et al. 2013). The diagnosis of VPSP in life is also challenging and should be aided by the agreement of clinical diagnostic criteria. The development of new diagnostic tests is encouraging in this respect, and researchers are hopeful that methods such as RT-QuIC will be widely used to aid the early diagnosis of sCJD (McGuire et al. 2012), which in turn will facilitate clinical trials to help identify potential treatments.

The acquired human prion diseases now appear to be in decline—kuru is extinct, iCJD is under control, and although new cases of vCJD are becoming increasingly rare (Collinge et al. 2008; Garske and Ghani 2010; Brown et al. 2012), a recent vCJD case in the United Kingdom has occurred in an individual who is heterozygous (M/V) at *PRNP* codon 129, raising the possibility of further cases in this genotype. A question also remains over the prevalence of asymptomatic vCJD infection, at least in the United Kingdom, and researchers are hopeful that the figures derived from tissue-based prevalence studies will be refined and made more accurate when screening tests are developed. These screening tests may also be applicable in a wider context (e.g., on individuals donating blood or about to undergo surgery); these uses will require further ethical considerations, preferably before the science has developed sufficiently to make vCJD screening a reality (Turner 2006).

## ACKNOWLEDGMENTS

The National Creutzfeldt–Jakob Disease Surveillance Unit is supported by the Scottish

Government and the Department of Health, England. The views expressed in this publication are those of the authors and not necessarily those of the Department of Health. We are most grateful to our colleagues, Dr. Mark W. Head and Dr. Diane L. Ritchie, for providing images and for reviewing the manuscript; Jan Mackenzie for data analysis and preparing the manuscript; and David Summers and Alison Green for providing figures.

## REFERENCES

- Alcalde-Cabero E, Almazán-Isla J, Brandel JP, Breithaupt M, Catarino J, Collins S, Haybäck J, Höftberger R, Kahana E, Kovacs GG, et al. 2012. Health professionals and risk of sporadic Creutzfeldt–Jakob disease, 1965 to 2010. *Euro-surveillance* **17**: 1–10.
- Barbot C, Castro L, Oliveira C, Carpenter C. 2010. Variant Creutzfeldt–Jakob disease: The first confirmed cases from Portugal shows early onset, long duration and unusual pathology. *J Neurol Neurosurg Psychiatry* **81**: 112–115.
- Binelli S, Agazzi P, Giaccone G, Will RG, Bugiani O, Franceschetti S, Tagliavini F. 2006. Periodic electroencephalogram complexes in a patient with variant Creutzfeldt–Jakob disease. *Ann Neurol* **59**: 423–427.
- Bishop MT, Ritchie DL, Will RG, Ironside JW, Head MW, Thomson V, Bruce M, Manson JC. 2008. No major change in vCJD agent strain after secondary transmission via blood transfusion. *PLoS ONE* **3**: 1–6.
- Bishop MT, Will RG, Manson JC. 2010. Defining sporadic Creutzfeldt–Jakob disease strains and their transmission properties. *Proc Natl Acad Sci* **107**: 12005–12010.
- Bishop MT, Diack AB, Ritchie DL, Ironside JW, Will RG, Manson JC. 2013. Prion infectivity in the spleen of a PRNP heterozygous individual with subclinical variant Creutzfeldt–Jakob disease. *Brain* **136**: 1139–1145.
- Boelle PY, Thomas G, Valleron AJ, Cesbron JY, Will R. 2003. Modelling the epidemic of variant Creutzfeldt–Jakob disease in the UK based on age characteristics: Updated, detailed analysis. *Stat Methods Med Res* **12**: 221–233.
- Brandel JP, Preece M, Brown P, Croes E, Laplanche JL, Agid Y, Will R, Alperovitch A. 2003. Distribution of codon 129 genotype in human growth hormone-treated CJD patients in France and the UK. *Lancet* **362**: 128–130.
- Brandner S, Whitfield J, Boone K, Puwa A, O'Malley C, Linehan JM, Joiner S, Scaravilli F, Calder I, Alpers M, et al. 2008. Central and peripheral pathology of kuru: Pathological analysis of a recent case and comparison with other forms of human prion disease. *Phil Trans R Soc Lond B Biol Sci* **363**: 3755–3763.
- Brown P, Rodgers-Johnson P, Cathala F, Gibbs CJ Jr, Gajdusek DC. 1984. Creutzfeldt–Jakob disease of long duration: Clinicopathological characteristics, transmissibility, and differential diagnosis. *Ann Neurol* **16**: 295–304.
- Brown P, Preece M, Brandel JP, Sato T, McShane L, Zerr I, Fletcher A, Will RG, Pocchiari M, Cashman NR, et al. 2000. Iatrogenic Creutzfeldt–Jakob disease at the millennium. *Neurology* **55**: 1075–1081.
- Brown P, Brandel JP, Sato T, Nakamura Y, Mackenzie J, Will RG, Ladogana A, Pocchiari M, Leschek EW, Schonberger LB. 2012. Iatrogenic Creutzfeldt–Jakob disease, final assessment. *Emerg Infect Dis* **18**: 901–907.
- Bruce ME, Will RG, Ironside JW, McConnell I, Drummond D, Suttie A, McCordle L, Chree A, Hope J, Birkett C, et al. 1997. Transmissions to mice indicate that “new variant” CJD is caused by the BSE agent. *Nature* **389**: 498–501.
- Bruce ME, McConnell I, Will RG, Ironside JW. 2001. Detection of variant Creutzfeldt–Jakob disease infectivity in extraneural tissues. *Lancet* **358**: 208–209.
- Chohan G. 2013. Correlative study of the clinical, pathological and biochemical features of sporadic CJD. MD thesis, University of Edinburgh, UK.
- Colby DW, Prusiner SB. 2011. Prions. *Cold Spring Harb Perspect Biol* **3**: a006833.
- Collie DA, Summers DM, Sellar RJ, Ironside JW, Cooper S, Zeidler M, Knight R, Will RG. 2003. Diagnosing variant Creutzfeldt–Jakob disease with the pulvinar sign: MR imaging findings in 86 neuropathologically confirmed cases. *Am J Neuroradiol* **24**: 1560–1569.
- Collinge J, Sidle KC, Meads J, Ironside J, Hill AF. 1996. Molecular analysis of prion strain variation and the aetiology of “new variant” CJD. *Nature* **383**: 685–690.
- Collinge J, Whitfield J, McKintosh E, Beck J, Mead S, Thomas DJ, Alpers MP. 2006. Kuru in the 21st century—An acquired human prion disease with very long incubation periods. *Lancet* **367**: 2068–2074.
- Collinge J, Whitfield J, McKintosh E, Frosh A, Mead S, Hill AF, Brandner S, Thomas D, Alpers MP. 2008. A clinical study of kuru patients with long incubation periods at the end of the epidemic in Papua New Guinea. *Phil Trans R Soc Lond B Biol Sci* **363**: 3725–3739.
- Cooper JD, Bird SM. 2002. UK dietary exposure to BSE in beef mechanically recovered meat: By birth cohort and gender. *J Cancer Epidemiol Prev* **7**: 59–70.
- Cooper SA, Heath CA, Will RG, Knight RS. 2005. Visual loss at onset of sporadic Creutzfeldt–Jakob disease: Making sense of the “Heidenhain variant.” *J Neurol Neurosurg Psychiatry* **76**: 156.
- Cooper SA, Murray KL, Heath CA, Will RG, Knight RS. 2006. Sporadic Creutzfeldt–Jakob disease with cerebellar ataxia at onset in the United Kingdom. *J Neurol Neurosurg Psychiatry* **77**: 1273–1275.
- Cousens SN, Zeidler M, Esmonde TF, De Silva R, Wilesmith JW, Smith PG, Will RG. 1997. Sporadic Creutzfeldt–Jakob disease in the United Kingdom: Analysis of epidemiological surveillance data for 1970–96. *BMJ* **315**: 389–395.
- Creutzfeldt HG. 1920. On a particular focal disease of the central nervous system (preliminary communication). *Z Ges Neurol Psychiat* **57**: 1–18.
- de Pedro Cuesta J, Mahillo-Fernández I, Rábano A, Calero M, Cruz M, Siden A, Laursen H, Falkenhorst G, Mølbak K; EUROSURGYCJD Research Group. 2011. Nosocomial transmission of sporadic Creutzfeldt–Jakob disease: Results from a risk-based assessment of surgical interventions. *J Neurol Neurosurg Psychiatry* **82**: 204–212.

- de Pedro Cuesta J, Ruiz Tovar M, Ward H, Calero M, Smith A, Verduras CA, Pocchiari M, Turner ML, Forland F, Palm D, et al. 2012. Sensitivity to biases of case-control studies on medical procedures, particularly surgery and blood transfusion, and risk of Creutzfeldt–Jakob disease. *Neuroepidemiology* **39**: 1–18.
- de Pedro Cuesta J, Mahillo-Fernández I, Calero M, Rábano A, Cruz M, Siden A, Martínez-Martin P, Laursen H, Ruiz-Tovar M, Mølbak K, et al. 2014. Towards an age-dependent transmission model of acquired and sporadic Creutzfeldt–Jakob disease. *PLoS ONE* **9**: e109412.
- Diack AB, Ritchie DL, Peden AH, Brown D, Boyle A, Morabito L, MacLennan D, Burgoyne P, Jansen C, Knight RS, et al. 2014. Variably protease-sensitive prionopathy, a unique prion variant with inefficient transmission properties. *Emerg Infect Dis* **20**: 1969–1979.
- Dorsey K, Zou S, Schonberger LB, Sullivan M, Kessler D, Notari E IV, Fang CT, Dodd RY. 2009. Lack of evidence of transfusion transmission of Creutzfeldt–Jakob disease in a US surveillance study. *Transfusion* **49**: 977–984.
- Edgeworth JA, Farmer M, Sicilia A, Tavares P, Beck J, Campbell T, Lowe J, Mead S, Rudge P, Collinge J, et al. 2011. Detection of prion infection in variant Creutzfeldt–Jakob disease: A blood-based assay. *Lancet* **377**: 487–493.
- Gajdusek DC, Gibbs CJ Jr, Alpers M. 1966. Experimental transmission of a kuru-like syndrome in chimpanzees. *Nature* **209**: 794–796.
- Gambetti P, Dong Z, Yuan J, Xiao X, Zheng M, Alshekhlee A, Castellani R, Cohen M, Barria MA, Gonzalez-Romero D, et al. 2008. A novel human disease with abnormal prion protein sensitive to protease. *Ann Neurol* **63**: 697–708.
- Garske T, Ghani AC. 2010. Uncertainty in the tail of the variant Creutzfeldt–Jakob disease epidemic in the UK. *PLoS ONE* **5**: e15626.
- Gibbs CJ, Gajdusek DC, Asher DM, Alpers HP, Beck E, Daniel PM, Matthews WB. 1968. Creutzfeldt–Jakob disease (spongiform encephalopathy): Transmission to the chimpanzee. *Science* **161**: 388–389.
- Gill ON, Spencer Y, Richard-Loendt A, Kelly C, Dabaghian R, Boyes L, Linehan J, Simmons M, Webb P, Bellerby P, et al. 2013. Prevalent abnormal prion protein in human appendixes after bovine spongiform encephalopathy epizootic: Large scale survey. *BMJ* **347**: f5675.
- Glatzel M, Abela E, Maissen M, Aguzzi A. 2003. Extraneural pathologic prion protein in sporadic Creutzfeldt–Jakob disease. *New Engl J Med* **349**: 1812–1820.
- Green AJ, Thompson EJ, Stewart GE, Zeidler M, Mackenzie JM, Macleod MA, Ironside JW, Will RG, Knight RS. 2001. Use of 14-3-3 and other brain-specific proteins in CSF in the diagnosis of variant Creutzfeldt–Jakob disease. *J Neurol Neurosurg Psychiatry* **70**: 744–748.
- Green A, Sanchez-Juan P, Ladogana A, Cuadrado-Corrales N, Sánchez-Valle R, Mitrová E, Stoeck K, Sklaviadis T, Kulczycki J, Heinemann U, et al. 2007. CSF analysis in patients with sporadic CJD and other transmissible spongiform encephalopathies. *Eur J Neurol* **14**: 121–124.
- Hadlow WJ. 1959. Scrapie and kuru. *Lancet* **2**: 289–290.
- Head MW, Ironside JW. 2012. Review: Creutzfeldt–Jakob disease: Prion protein type, disease phenotype and agent strain. *Neuropathol Appl Neurobiol* **38**: 296–310.
- Head MW, Ritchie D, Smith N, McLoughlin V, Nailon W, Samad S, Masson S, Bishop M, McCardle L, Ironside JW. 2004. Peripheral tissue involvement in sporadic, iatrogenic, and variant Creutzfeldt–Jakob disease: An immunohistological, quantitative and biochemical study. *Am J Pathol* **164**: 143–153.
- Head MW, Yull HM, Ritchie DL, Langeveld JP, Fletcher NA, Knight RS, Ironside JW. 2013. Variably protease-sensitive prionopathy in the UK: A retrospective review 1991–2008. *Brain* **136**: 1102–1115.
- Heath CA, Will RG. 2008. Clinical aspects of variant Creutzfeldt–Jakob disease. In *Handbook of clinical neurology*, Vol. 89 (3rd series) (ed. Duyckaerts C), pp. 765–778. Elsevier, Amsterdam.
- Heath CA, Barker RA, Esmonde TF, Harvey P, Trend P, Head MW, Smith C, Bell JE, Ironside JW, Will RG, et al. 2006. Dura mater-associated Creutzfeldt–Jakob disease: Experience from surveillance in the UK. *J Neurol Neurosurg Psychiatry* **77**: 880–882.
- Hewitt PE, Llewelyn CA, Mackenzie J, Will RG. 2006. Creutzfeldt–Jakob disease and blood transfusion: Results of the UK Transfusion Medicine Epidemiology Review study. *Vox Sanguinis* **91**: 221–230.
- Hill AF, Desbruslais M, Joiner S, Sidle KA, Gowland I, Collinge J. 1997a. The same prion strain causes vCJD and BSE. *Nature* **389**: 448–450.
- Hill AF, Zeidler M, Ironside J, Collinge J. 1997b. Diagnosis of new variant Creutzfeldt–Jakob disease by tonsil biopsy. *Lancet* **349**: 99–100.
- Hill AF, Butterworth RJ, Joiner S, Jackson G, Rossor MN, Thomas DJ, Frosh A, Tolley N, Bell JE, Spencer M, et al. 1999. Investigation of variant Creutzfeldt–Jakob disease and other human prion diseases with tonsil biopsy samples. *Lancet* **353**: 183–189.
- Hilton DA, Ghani AC, Conyers L, Edwards P, McCardle L, Ritchie D, Penney M, Hegazy D, Ironside JW. 2004. Prevalence of lymphoreticular prion protein accumulation in UK tissue samples. *J Pathol* **203**: 733–739.
- Ironside JW, Ritchie DL, Head MW. 2005. Phenotypic variability in human prion diseases. *Neuropathol Appl Neurobiol* **31**: 565–579.
- Ironside JW, Bishop MT, Connolly K, Hegazy D, Lowrie S, Le Grice M, Ritchie DL, McCardle LM, Hilton DA. 2006. Variant Creutzfeldt–Jakob disease: Prion protein genotype analysis of positive appendix tissue samples from a retrospective prevalence study. *BMJ* **332**: 1186–1188.
- Ironside JW, Ghetti B, Head MW, Piccardo P, Will RG. 2008. Prion diseases. In *Greenfield's neuropathology*, 8th ed., pp. 1197–1273. Hodder Arnold, London, pp. 1197–1273.
- Jakob A. 1921. On a disease of the central nervous system clinically related to multiple sclerosis (spastic pseudo sclerosis) with remarkable anatomical findings. *Medizinische Klinik* **13**: 372–376.
- Jansen C, Head MW, Rozemuller AJ, Ironside JW. 2009. Panencephalopathic Creutzfeldt–Jakob disease in the Netherlands and the UK: Clinical and pathological characteristics of nine patients. *Neuropathol Appl Neurobiol* **35**: 272–282.
- Jaumuktane Z, Mead S, Ellis M, Wadsworth JD, Nicoll AJ, Kenny J, Launchbury F, Linehan J, Richard-Loendt A, Walker AS, et al. Evidence for human transmission of

- amyloid- $\beta$  pathology and cerebral amyloid angiopathy. 2015. *Nature* **525**: 247–250.
- Kovacs GG, Peden A, Weis S, Höftberger R, Berghoff AS, Yull H, Ströbel T, Koppi S, Katzenschlager R, Langenscheidt D, et al. 2013. Rapidly progressive dementia with thalamic degeneration and peculiar cortical prion protein immunoreactivity, but absence of proteinase K resistant PrP: A new disease entity? *Acta Neuropathol Commun* **1**: 72.
- Lacroux C, Comoy E, Moudjou M, Perret-Liaudet A, Lukan S, Litaise C, Simmons H, Jas-Duval C, Lantier I, Béringue V, et al. 2014. Preclinical detection of variant CJD and BSE prions in blood. *PLoS ONE* **10**: e1004202.
- Ladogana A, Puopolo M, Croes EA, Budka H, Jarius C, Collins S, Klug GM, Sutcliffe T, Giulivi A, Alperovitch A, et al. 2005. Mortality from Creutzfeldt–Jakob disease and related disorders in Europe, Australia, and Canada. *Neurology* **64**: 1586–1591.
- Liberski PP, Sikorska B, Lindenbaum S, Goldfarb LG, McLean C, Hainfellner JA, Brown P. 2012. Kuru: Genes, cannibals and neuropathology. *J Neuropathol Exp Neurol* **71**: 92–103.
- McGuire LI, Peden AH, Orrú CD, Wilham JM, Appleford NE, Mallinson G, Andrews M, Head MW, Caughey B, Will RG, et al. 2012. Real time quaking-induced conversion analysis of cerebrospinal fluid in sporadic Creutzfeldt–Jakob disease. *Ann Neurol* **72**: 278–285.
- McNaughton HK, Will RG. 1997. Creutzfeldt–Jakob disease presenting acutely as stroke: An analysis of 30 cases. *Neurol Infect Epidemiol* **2**: 19–24.
- Meissner B, Kallenberg K, Sanchez-Juan P, Collie D, Summers DM, Almonti S, Collins SJ, Smith P, Cras P, Jansen GH, et al. 2009a. MRI lesion profiles in sporadic Creutzfeldt–Jakob disease. *Neurology* **72**: 1994–2001.
- Meissner B, Kallenberg K, Sanchez-Juan P, Ramljak S, Krasnianski A, Heinemann U, Eigenbrod S, Gelpi E, Barsic B, Kretzschmar HA, et al. 2009b. MRI and clinical syndrome in dura mater-related Creutzfeldt–Jakob disease. *J Neurol* **256**: 355–363.
- Moda F, Suardi S, Di Fede G, Indaco A, Limido L, Vimercati C, Ruggerone M, Campagnani I, Langeveld J, Terruzzi A, et al. 2012. MM2-thalamic Creutzfeldt–Jakob disease: Neuropathological, biochemical and transmission studies identify a distinctive prion strain. *Brain Pathol* **22**: 662–669.
- Moda F, Gambetti P, Notari S, Concha-Marambio L, Catania M, Park KW, Mederna E, Suardi S, Haik S, Brandel JP, et al. 2014. Prions in the urine of patients with variant Creutzfeldt–Jakob disease. *New Engl J Med* **371**: 530–539.
- Neumann MA, Gajdusek DC, Zigas V. 1964. Neuropathologic findings in exotic neurologic disorders among natives of the highlands of New Guinea. *J Neuropathol Exp Neurol* **23**: 486–507.
- Notari S, Moleres FJ, Hunter SB, Belay ED, Schonberger LB, Cali I, Parchi P, Shieh WJ, Brown P, Zaki S, et al. 2010. Multiorgan detection and characterization of protease-resistant prion protein in a case of variant CJD examined in the United States. *PLoS ONE* **5**: e8765.
- Notari S, Xiao X, Espinosa JC, Cohen Y, Quing L, Aguilar-Calvo P, Kofskey D, Cali I, Cracco L, Kong Q, et al. 2014. Transmission characteristics of variably protease-sensitive prionopathy. *Emerg Infect Dis* **12**: 2006–2014.
- Orrú CD, Bongianni M, Tonoli G, Ferrari S, Hughson AG, Groveman BR, Fiorini M, Pocchiari M, Monaco S, Caughey B, et al. 2014. A test for Creutzfeldt–Jakob disease using nasal brushings. *New Engl J Med* **371**: 519–529.
- Parchi P, Castellani R, Capellari S, Ghetti B, Young K, Chen SG, Farlow M, Dickson DW, Sima AA, Trojanowski JQ, et al. 1996. Molecular basis of phenotypic variability in sporadic Creutzfeldt–Jakob disease. *Ann Neurol* **39**: 767–778.
- Parchi P, Capellari S, Chen SG, Petersen RB, Gambetti P, Knopp N, Brown P, Kitamoto T, Tateishi J, Giese A, et al. 1997. Typing prion isoforms. *Nature* **386**: 232–234.
- Parchi P, Giese A, Capellari S, Brown P, Schulz-Schaeffer W, Windl O, Zerr I, Budka H, Kopp N, Piccardo P, et al. 1999. Classification of sporadic Creutzfeldt–Jakob disease based on molecular and phenotypic analysis of 300 subjects. *Ann Neurol* **46**: 224–233.
- Parchi P, Strammiello R, Notari S, Giese A, Langeveld JP, Ladogana A, Zerr I, Roncaroli F, Cras P, Ghetti B, et al. 2009. Incidence and spectrum of sporadic Creutzfeldt–Jakob disease variants with mixed phenotype and co-occurrence of PrP<sup>Sc</sup> types: An updated classification. *Acta Neuropathol* **118**: 659–671.
- Peden AH, Head MW, Ritchie DL, Bell JE, Ironside JW. 2004. Preclinical vCJD after blood transfusion in a PRNP codon 129 heterozygous patient. *Lancet* **364**: 527–529.
- Peden AH, Ritchie DL, Uddin HP, Daen AF, Schiller KA, Head MW, Ironside JW. 2007. Abnormal prion protein in the pituitary in sporadic and variant Creutzfeldt–Jakob disease. *J Gen Virol* **88**: 1068–1072.
- Peden A, McCardle L, Head MW, Love S, Ward HJ, Cousens SN, Keeling DM, Millar CM, Hill FG, Ironside JW. 2010. Variant CJD infection in the spleen of a neurologically asymptomatic UK adult patient with haemophilia. *Haemophilia* **16**: 296–304.
- Prusiner SB. 2013. Biology and genetics of prions causing neurodegeneration. *Annu Rev Genet* **47**: 601–623.
- Puopolo M, Ladogana A, Vetrugno V, Pocchiari M. 2011. Transmission of sporadic Creutzfeldt–Jakob disease by blood transfusion: Risk factor or possible biases. *Transfusion* **51**: 1556–1566.
- Rudge P, Jaumuktane Z, Adlard P, Bjurstrom N, Caine D, Lowe J, Norsworthy P, Hummerich H, Drueyeh R, Wadsworth JDF, et al. 2015. Iatrogenic CJD due to pituitary-derived growth hormone with genetically determined incubation times of up to 40 years. *Brain* **138**: 3386–3399.
- Scott MR, Will RG, Ironside J, Nguyen HO, Tremblay P, DeArmond SJ, Prusiner SB. 1999. Compelling transgenic evidence for transmission of bovine spongiform encephalopathy prions to humans. *Proc Natl Acad Sci* **96**: 15137–15142.
- St Rose SG, Hunter N, Matthews L, Foster JD, Chase-Topping ME, Kruuk LE, Shaw DJ, Rhind SM, Will RG, Woolhouse ME. 2006. Comparative evidence for a link between Peyer’s patch development and susceptibility to transmissible spongiform encephalopathies. *BMC Infect Dis* **6**: 5.

- Turner M. 2006. Transfusion safety with regards to prions: Ethical, legal and societal considerations. *Transfus Clin Biol* **13**: 317–319.
- Valleron AJ, Boelle PY, Will R, Cesbron JY. 2001. Estimation of epidemic size and incubation time based on age characteristics of vCJD in the United Kingdom. *Science* **294**: 1726–1728.
- Wadsworth JD, Joiner S, Linehan J, Desbruslais M, Fox K, Cooper S, Cronier S, Asante EA, Mead S, Brandner S, et al. 2008. Kuru prions and sporadic Creutzfeldt–Jakob disease prions have equivalent transmission properties in transgenic and wild-type mice. *Proc Natl Acad Sci* **105**: 3885–3890.
- Ward HJ, Everington D, Cousens SN, Smith-Bathgate B, Leitch M, Cooper S, Heath C, Knight RS, Will RG. 2006. Risk factors for variant Creutzfeldt–Jakob disease: A case-control study. *Ann Neurol* **59**: 111–120.
- Ward HJ, Everington D, Cousens SN, Smith-Bathgate B, Gillies M, Murray K, Knight RS, Smith PG, Will RG. 2008. Risk factors for sporadic Creutzfeldt–Jakob disease. *Ann Neurol* **63**: 347–354.
- Will RG. 2002. Clinical features of human prion diseases. In *Diseases of the nervous system*, 3rd ed. (ed. Asbury AK, et al.) pp. 1716–1727. Cambridge University Press, Cambridge.
- Will B. 2010. Variant CJD: Where has it gone, or has it? *Pract Neurol* **10**: 250–251.
- Will RG. 2014. Prions and agents of TSEs. In *Encyclopedia of food safety*, Vol. 2, pp. 12–17. Elsevier, Amsterdam.
- Will RG, Ironside JW, Zeidler M, Cousens SN, Estibeiro K, Alperovitch A, Poser S, Pocchiari M, Hofman A, Smith PG. 1996. A new variant of Creutzfeldt–Jakob disease in the UK. *Lancet* **347**: 921–925.
- Yamada M. 2006. The first Japanese case of variant Creutzfeldt–Jakob disease showing periodic electroencephalogram. *Lancet* **367**: 874.
- Yamada M, Noguchi-Shinohara M, Hamaguchi T, Nozaki I, Kitamoto T, Sato T, Nakamura Y, Mizusawa H. 2009. Dura mater graft-associated Creutzfeldt–Jakob disease in Japan: Clinicopathological and molecular characterization of the two distinct subtypes. *Neuropathology* **29**: 609–618.
- Zeidler M, Johnstone EC, Bamber RW, Dickens CM, Fisher CJ, Francis AE, Goldbeck R, Higgs R, Johnson-Sabine EC, Lodge GJ, et al. 1997a. New variant Creutzfeldt–Jakob disease: Psychiatric features. *Lancet* **350**: 908–910.
- Zeidler M, Stewart GE, Barraclough CR, Bateman DE, Bates D, Burn DJ, Colchester AC, Durward W, Fletcher NA, Hawkins SA, et al. 1997b. New variant Creutzfeldt–Jakob disease: Neurological features and diagnostic tests. *Lancet* **350**: 903–907.
- Zerr I, Pocchiari M, Collins S, Brandel JP, de Pedro Cuesta J, Knight RS, Bernheimer H, Cardone F, Delasnerie-Laupretre N, Cuadrado Corrales N, et al. 2000. Analysis of EEG and CSF 14-3-3 proteins as aids to the diagnosis of Creutzfeldt–Jakob disease. *Neurology* **55**: 811–815.
- Zou WQ, Puoti G, Xiao X, Yuan J, Qing L, Cali I, Shimoji M, Langeveld JP, Castellani R, Notari S, et al. 2010. Variably protease-sensitive prionopathy: A new sporadic disease of the prion protein. *Ann Neurol* **68**: 162–172.